

Dentinogenesis imperfecta: a case report of comprehensive treatment for a teenager

Rick Biethman, DMD ■ Laura Richards Capati, DMD, MA ■ Nicole Eldger, DMD

Improving a smile can change a person's self-image. This case report describes treatment for an adolescent boy with *dentinogenesis imperfecta*. Soon to begin high school, the 14-year-old patient was severely obese and disliked his stained teeth. A combination of surgical periodontal treatment, endodontic treatment, and veneers improved both his smile

and self-perception—which may have played a role in achieving his weight loss goal of 125 lb at 12 months post-treatment.

Received: March 18, 2013

Accepted: June 13, 2013

D*entinogenesis imperfecta* type II is an inherited genetic disorder that affects the structural integrity of the dentin, with an incidence of 1:6000-8000 live births.¹ Clinical symptoms include yellowish-brown or bluish-grey discoloration and substantial translucency of the teeth. Histologically, these teeth show a limited number or complete lack of dentinal tubules, with dentin mineralization either significantly reduced or defective. Due to the resultant softness of the underlying dentin of these teeth, the enamel tends to break down, leading to rapid and progressive attrition. Radiologically, these teeth show bulbous crowns with cervical constrictions at the root junction. Roots are smaller and narrower compared to healthy teeth. Pulp chambers and root canals are usually obliterated.¹ The obliterated pulpal canals make conventional endodontic therapy difficult, if not impossible.² Affected teeth (especially posterior teeth) often need to be extracted due to severe wear or fracture; in addition, the appearance of the anterior teeth is often unesthetic due to discoloration.³

According to Malkinson et al, both dental professionals and lay people perceive a person's attractiveness, friendliness, trustworthiness, intelligence, and self-confidence to be inversely related to the amount of gingival that person displays.⁴ Similarly, a study of university students by Gleber-Netto et al reported that the discoloration from mild and moderate fluorosis was considered unattractive.⁵ Kloth et al reported that an attractive smile can enhance positive eye contact between individuals.⁶ According to a 2011 Jordanian study, a majority of people perceive a midline diastema to be unattractive.⁷

Obesity has been linked to many chronic health problems seen in adults, including Type II diabetes, hypertension, coronary artery disease, stroke, and arthritis.⁸ Yuan et al reported a strong association between obesity and periodontal disease.⁹ Franchini et al suggested that gingivitis in overweight and obese adolescents may be due to a combination of metabolic and inflammatory profiles, as well as a tendency toward neglecting oral hygiene.¹⁰ This case report describes an adolescent suffering from both obesity and *dentinogenesis imperfecta*.

Case report

Three months before starting his freshman year of high school, a 14-year-old adolescent sought to improve his smile. The patient had just moved into the area, was severely obese, and disliked his short brown teeth with spaces. The patient's maternal grandmother, mother, uncle, and sister all exhibited signs of *dentinogenesis imperfecta* type II in both the primary and adult dentition.

A review of the patient's medical history noted that he was 5 feet, 10 inches tall and weighed 300 lb. Other than obesity, his health history was normal. He had attempted to lose weight multiple times in the previous 6 years. He was not taking any medications, and a consultation with his orthopedic surgeon confirmed no signs of *osteogenesis imperfecta*. His growth plates were closed, which correlated with published evidence that obese children tend to exhibit increased skeletal growth earlier in life along with an earlier onset of puberty; thus additional postpuberty skeletal growth in these patients is rare.¹¹ The premature closure of skeletal growth is thought to be due to the excess estradiol produced in fat

cells and their subsequent effect on the epiphyseal plates.¹²

Diagnostic study models were obtained and mounted; in addition, a full-mouth series of radiographs and clinical photos were taken and reviewed. Clinical examination revealed no missing teeth and a low caries index. Seven years earlier, the patient had composite veneers placed on teeth No. 7-10 to hide tooth discoloration. Generalized moderate gingivitis was noted. The patient had a Class I occlusion and no signs of posterior wear or bruxism. A periapical lesion was seen on tooth No. 7 which had no signs of decay. The tooth display on teeth No. 8 and 9 was 7 mm, and a 1 mm diastema was noted between teeth No. 8 and 9.

A treatment plan was formulated, and a diagnostic wax-up and computer simulation of the proposed changes were shown to the patient and his parents, who accepted them (Fig. 1-3, Table).

The patient received an adult prophylaxis, oral hygiene instructions, and a prescription for a chlorhexidine rinse. Two weeks later, surgical crown lengthening was performed on the facial aspect of teeth No. 3-14 to reposition the gingival tissues at normal adult levels. The patient's gingiva had been at the normal position for a 14-year-old, with the cemento-enamel junction (CEJ) approximately 3 mm subgingival. Without intervention, the gingiva would have moved to the normal adult position in 4-6 years through the process of passive eruption. A facial full thickness flap was reflected, to expose the CEJ. The alveolar bone was removed from the facial and interproximal aspects, positioning the bone 3 mm apical to the CEJ. The facial flap was

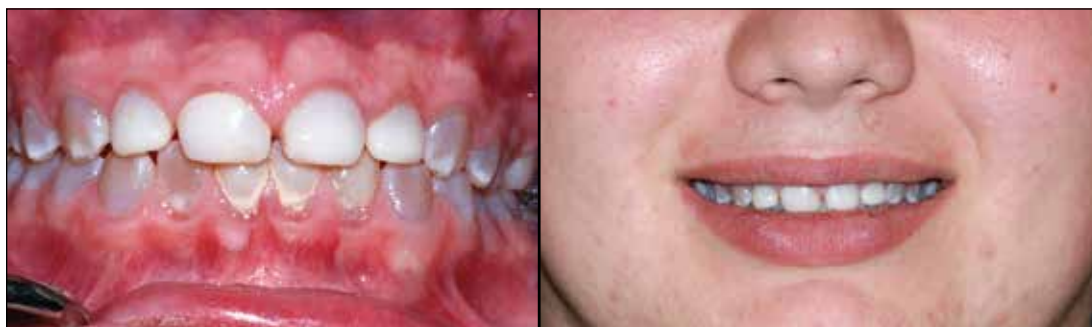

Fig. 1. *Left.* Pretreatment close up of anterior teeth. *Right.* Facial view of patient's smile pretreatment.

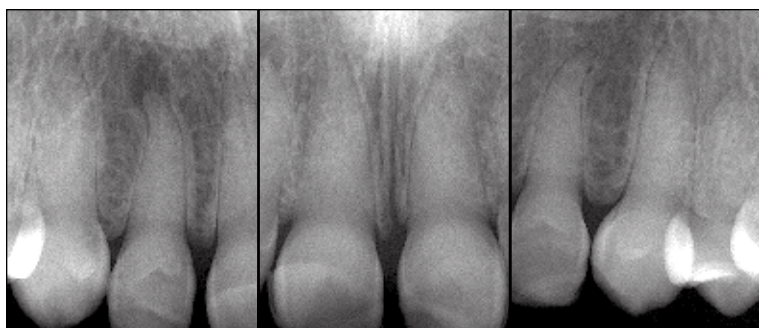


Fig. 2. Pretreatment radiographs.

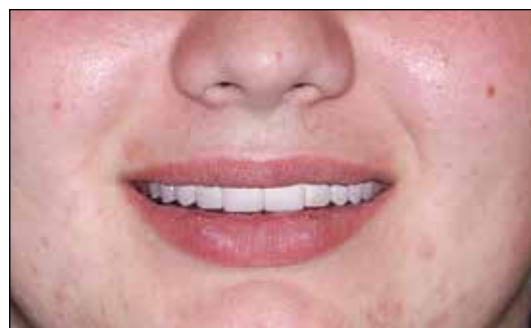

Fig. 3. Computer simulation of anticipated results.

Table. Clinical findings and treatment.

Clinical finding	Problem	Treatment
Periodontal	Moderate gingivitis	Adult prophyl, oral hygiene instructions
Operative	Decay on tooth No. 5 distal	Removal of decay and resin restoration
	Decay on tooth No. 9 occlusal	Removal of decay and resin restoration
Endodontic	Periapical lesion on tooth No. 7	Apicoectomy on tooth No. 7
Occlusal	Class 1 occlusion	No treatment needed
	Potential for significant wear	Hard acrylic bite guard
Oral Surgery	Impacted teeth No. 1, 16, 17, and 32	Surgical removal
Esthetic	Short clinical crowns on teeth No. 3-14	Crown lengthening of teeth No. 3-14
	Discolored teeth	Porcelain veneers on teeth No. 6-11
		Direct resin veneers on teeth No. 4, 5, 12, and 13
Social	Patient plays football and wrestling	Custom fabricated mouthguard

repositioned and sutured to place it 3 mm above the bone crest. Previously published studies have determined that the gingival position will stabilize 3 mm above the bone crest 3 months postsurgery, with possible minor additional changes taking place for up to 6 months postsurgery.¹³⁻¹⁵

The gingival tissues were allowed to heal for 10 weeks; at that time, conservative veneer preparations were placed on teeth No. 6-11. A facial reduction of 0.75 mm was attempted to bond the veneer to enamel while masking the underlying dark dentin. The gingival

finish line was placed 1 mm supragingival. Bis-acryl resin temporaries were bonded by etching a 3 mm portion in the middle of each tooth. These steps were accomplished before the start of the high school year. The patient was very happy with the changes in his appearance. At the next appointment—13 weeks after the crown-lengthening surgery—decay was removed and restorations placed on teeth No. 5 and 9. The veneer preparations on teeth No. 6-11 were refined, and the gingival margins were placed at the gingival crest on enamel. Next, the porcelain veneers were bonded in place on teeth No. 6-11 (Fig. 4-6). Direct resin veneers were placed on teeth No. 4, 5, 12, and 13, to build out the buccal profile and mask the discolored dentin. These teeth are in a less visible area, thus the conservative direct resin veneer approach was chosen. The patient was referred for an apicoectomy on tooth No. 7. The tooth was asymptomatic and had no decay, although a periapical radiolucency was detected on the full mouth series of radiographs. A clinical feature of

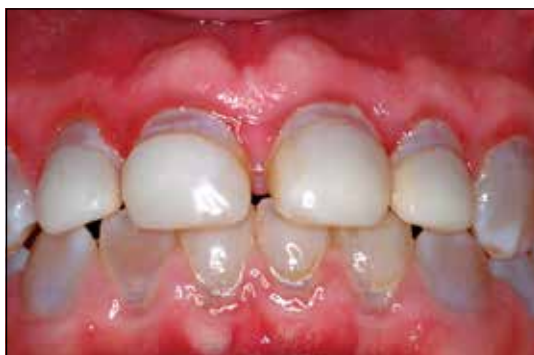

Fig. 4. 8 weeks post crown-lengthening surgery.

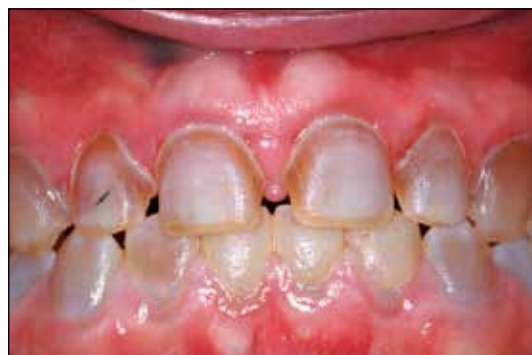

Fig. 5. Maxillary veneer preparations.

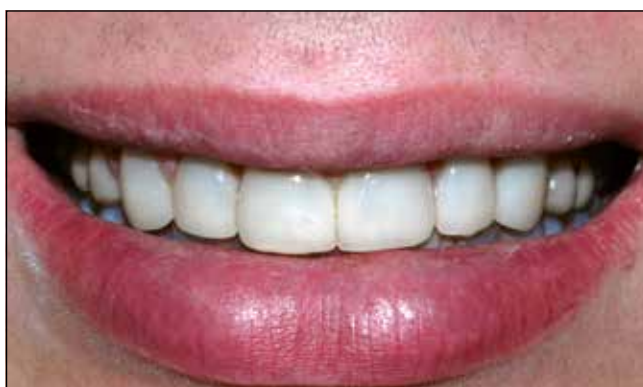

Fig. 6. Final smile (compare to Fig. 3).



Fig. 7. Photograph of patient at beginning of treatment.



Fig 8. Photograph of patient 1 year post-treatment.

dentinogenesis imperfecta is little or no pulpal tissue.² No pulpal canal could be seen on the patient's radiograph. To avoid compromising the structural integrity of the already weak dentin, it was decided to avoid conventional endodontic treatment through the tooth and instead perform apical access to debride the lesion and seal the tooth with an amalgam restoration.

Impressions of the final restorations were taken to create a bruxism appliance for nighttime wear and a mouthguard for wear during sports. Although the patient had not exhibited any signs of bruxism, it was decided that he would wear the bruxism appliance to protect the fragile enamel resulting from the impaired dentin that is usually found in cases of dentinogenesis imperfecta. The unerupted third molars were removed and the patient's active phase of treatment was completed. The total length of treatment

was 12 months. The patient was happy with the final outcome, and the diagnostic simulation was a reasonable prediction of the final results (Fig. 3 and 6).

The changes seen in the patient's overall self-perception and body image mirrored the changes made to his smile. He immediately felt better about his longer teeth after the crown lengthening. In his words, the old teeth looked like "baby teeth" and were too small for his body. He had been teased about the color and shape of his teeth for as long as he could remember. In the 6 weeks before veneer preparations started, the patient lost approximately 15 lb. He began a strenuous exercise routine and adjusted his food habits. As a result, he lost 125 lb in the 12 months after the start of dental treatment. His percentage of body fat was 51% at the start of dental care and stabilized at 11% after the weight loss.

The remarkable changes made by the patient in his overall appearance cannot be attributed solely to his improved smile. The patient had a history of dietary counseling, weight management programs, and exercise programs for the purpose of losing the excess weight. However, none of them had been successful at sustaining weight loss. It is plausible that his enhanced smile was the incentive he needed to utilize the weight loss skills acquired in his previous attempts. At a 1-year follow-up evaluation, his body fat percentage was still 11% and he had not regained any of the lost weight (Fig. 7 and 8).

Summary

Due to its infrequent occurrence, dentinogenesis imperfecta as documented in the available literature consists primarily of individual case studies. The dentition in patients with dentinogenesis imperfecta

will eventually break down and require extensive restorations supported by implants or dentures. The treatment in the present case was conservative while meeting the patient's esthetic needs. The use of the nighttime bite guard and the custom athletic mouthguard appliance should minimize damage to the patient's fragile teeth. The esthetic success achieved in this case improved the patient's self-image, confidence, and attitude.

Author information

Dr. Biethman is an assistant professor, Department of Restorative Dentistry, School of Dental Medicine, Southern Illinois University at Edwardsville, where Dr. Capati was a periodontal resident, and Dr. Eldger was an AEGD/Implant fellow.

References

1. Maciejewska I, Chomik E. Hereditary dentine diseases resulting from mutations in DSPP gene. *J Dent*. 2012; 40(7):542-548.
2. Pettiette MT, Wright JT, Trope M. *Dentinogenesis imperfecta*: endodontic implications. Case report. *Oral Surg Oral Med Oral Pathol Oral Radiol Endod*. 1998; 86(6):733-737.
3. Bencharit S, Byrd WC, Mack CR, Border MB, Wright JT. Full mouth rehabilitation for a patient with *dentinogenesis imperfecta*: a clinical report. *J Oral Implantol*. 2013 Jan 4 [Epub ahead of print].
4. Malkinson S, Waldrop TC, Gunsolley JC, Lanning SK, Sabatini R. The effect of esthetic crown lengthening on perceptions of a patient's attractiveness, friendliness, trustworthiness, intelligence, and self-confidence. *J Periodontol*. 2012;84(8):1126-1133.
5. Gleber-Netto FO, Diniz IM, Mudado FA, Fraga MG, Vargas AM. Assessment of aesthetic perceptions of mild and moderate dental fluorosis levels among students from the Federal University of Minas Gerais-UFMG, Brazil. *Oral Health Prev Dent*. 2011;9(4):339-345.
6. Kloth N, Altmann CS, Schweinberger SR. Facial attractiveness biases the perception of eye contact. *Q J Exp Psychol (Hove)*. 2011;64(10):1906-1918.
7. Abu Alhaija ES, Al-Shamsi NO, Al-Khateeb S. Perceptions of Jordanian laypersons and dental professionals to altered smile esthetics. *Eur J Orthod*. 2011;33(4): 450-456.
8. Flegal KM, Kit BK, Oprana H, Graubard BI. Association of all-cause mortality with overweight and obesity using standard body mass index categories: a systematic review and meta-analysis. *JAMA*. 2013;309(1):71-82.
9. Yuan JC, Lee DJ, Afshari FS, Galang MT, Sukotjo C. Dentistry and obesity: a review and current status in US predoctoral dental education. *J Dent Educ*. 2012; 76(9):1129-1136.
10. Franchini R, Petri A, Migliario M, Rimondini L. Poor oral hygiene and gingivitis are associated with obesity and overweight status in paediatric subjects. *J Clin Periodontol*. 2011;38(11):1021-1028.
11. De Simone M, Farello G, Palumbo M, et al. Growth charts, growth velocity and bone development in childhood obesity. *Int J Obes Relat Metab Disord*. 1995;19(12):851-857.
12. Sopher AB, Jean AM, Zwany SK, et al. Bone age advancement in prepubertal children with obesity and premature adrenarche: possible potentiating factors. *Obesity (Silver Spring)*. 2011;19(6):1259-1264.
13. Gargiulo A, Wentz F, Orban B. Dimensions and relations of the dento-gingival junction in humans. *J Periodontol*. 1961;32:261-267.
14. Nevins M, Skurow HM. The intracrevicular restorative margin, the biologic width, and maintenance of the gingival margin. *Int J Periodontics Restorative Dent*. 1984;4(3):30-49.
15. Hempton T, Dominici J. Contemporary crown-lengthening therapy: a review. *J Am Dent Assoc*. 2010;141(6): 647-655.